

## DOSE-DEPENDENT EFFECTS OF PARAQUAT ON C-REACTIVE PROTEIN, SOME LIPID PROFILE PARAMETERS AND HISTOLOGY OF TISSUES IN MALE ALBINO RATS.

<sup>x</sup>Akinloye, O.A., Abioye, O.A., Olaojoyetan, O.E., Awosika., O.T and Akinloye, D.I

Department of Biochemistry, Federal University of Agriculture. P.M.B 2240, Abeokuta, Nigeria.

Correspondence Author's Address:

<sup>z</sup>Dr Akinloye, O.A

Department of Biochemistry, Federal University of Agriculture, P.M.B 2240, Abeokuta, Nigeria.

Phone Number: +2348030824063 e-mail: [oaakin@yahoo.com](mailto:oaakin@yahoo.com)

(Received: April, 2013; Accepted: May, 2013)

### ABSTRACT

Paraquat is a highly toxic and widely-used herbicide with no antidote. Its toxicity in man and animals has been reported to cause severe acute and long term health problems which eventually could lead to death. Measurement of blood C-reactive protein level (CRP) serves as a useful screen for infections and inflammatory diseases. Since it is known that paraquat exerts its toxic effects through generation of reactive oxygen species which causes injury to the cells thereby causing inflammation, this study was designed to determine the dose-dependent effects of paraquat on C-reactive protein, cholesterol, triglycerides and histology of liver and kidney in rats. Thirty albino rats weighing between 150g and 200g, randomly divided into five groups of six rats in each group were used. Rats in group A serve as control and were given feed and water only freely. Rats in group B, C, D and E were treated orally with 15mg/kg (below sub-lethal dose), 25mg/kg (sub-lethal dose), 35mg/kg (below lethal dose) and 45mg/kg (below lethal dose) of paraquat dichloride respectively for a period of fourteen days. The blood plasma collected was analyzed for CRP (using an immune-turbidimetric assay method), cholesterol and triglycerides while liver and kidney excised from sacrificed rats were used for histopathological studies. The result obtained showed that the concentration of CRP ( $12.38 \pm 0.09$ mg/L), cholesterol ( $8.61 \pm 0.49$ mg/L) and triglycerides ( $189.47 \pm 2.59$ mg/L) in control group was significantly lower ( $p < 0.05$ ) than the other groups. The higher the concentration of paraquat administered, the higher its toxicity and the higher the levels of CRP, cholesterol and triglycerides. Histopathological findings revealed some pathologic conditions ranging from diffuse vacuolar degeneration of hepatocyte and glomerular mesangiolysis in the liver and kidney of paraquat-treated group respectively. This present study therefore suggests that the induction of inflammation and oxidative damage by paraquat could be accompanied by elevated C-reactive protein, cholesterol and triglycerides in albino rats which could point to or be an indication of paraquat toxicity.

**Keywords:** Dose-dependent, Paraquat, C-reactive Protein, Biochemical Parameters, Histology.

### INTRODUCTION

Paraquat (PQ) is a non-selective contact herbicide discovered in 1955 and was registered as herbicide in 1962 by ICI laboratories (Paraquat-Monograph, 2003). Chemically paraquat is 1,1'-dimethyl-4,4'-bipyridinium dichloride (Roberts *et al.*, 2002). It is a widely used and effective herbicide with a broad spectrum of activity. Paraquat, a highly toxic weed killer, was once promoted by the United States for use in Mexico to destroy marijuana plants. Research found that this herbicide was dangerous to workers who applied it to the plants (Robbe *et al.*, 2004). In agriculture, it is used as an active ingredient in different products for protection of crops and is rapidly absorbed by green plants (Paraquat-Monograph, 2006) where the toxic effects are due to the production of paraquat-free radicals which, after re-oxidation with oxygen molecules, cause disorder in photosynthesis (Luty

*et al.*, 1997). However in animals, it is a well characterized pneumotoxicant (Brooks, 1971) as it is absorbed through different routes and readily reaches all organs and tissues of the body and is not metabolized; instead, it is reduced to an unstable free radical, which is then reoxidized to form a cation and a superoxide anion.

Paraquat produces both histological and functional changes in lungs, kidneys, adrenal glands, liver and myocardium, causing multi-organ failure (Paraquat-Monograph, 2003). Paraquat has several mechanisms in inducing cytotoxicity (Fukushima *et al.*, 2002). In mice, when given in acute toxic dose (50 mg/kg), the animals showed signs of necrosis and inflammation of liver parenchyma (Dragin *et al.*, 2006).

C-reactive protein (CRP) is an acute-phase protein whose physiological role is to bind to phosphocholine expressed on the surface of dead or dying cells (and some types of bacteria) in order to activate the complement system via the C1q complex (Thompson *et al.*, 1999). CRP is synthesized by the liver (Kennelly *et al.*, 2009) in response to factors released by fat cells (adipocytes) (Pincus *et al.*, 2007). CRP is a member of the class of acute-phase reactants as its levels rise dramatically during inflammatory processes occurring in the body. This increment has been attributed to a rise in the plasma concentration of Interleukin-6 (IL-6), which is produced predominantly by macrophages (Kennelly *et al.*, 2009) as well as adipocytes (Pincus *et al.*, 2007).

Cholesterol and triglycerides are fats normally found in the body and are important as intermediary substances for normal body function. High levels of cholesterol (Sadava *et al.*, 2011) and triglycerides (Cameron, 1987) have been linked with cardiovascular diseases.

Previous studies generally reported the acute toxic effects of paraquat. The present study was designed to evaluate the dose-dependent effects of paraquat on C-reactive protein, cholesterol, triglycerides and histology of organs of biotransformation (i.e kidney and liver).

## MATERIALS AND METHODS

### Chemicals

Paraquat dichloride was purchased from the Ogun-State Agricultural Development Programme (OGADEP), Abeokuta, Nigeria. C-reactive protein (CRP) kit was obtained from Cypress diagnostics (UK), while cholesterol and triglycerides kits were the products of Fortress diagnostics. All other chemicals were of analytical grade.

### Experimental Animals

Thirty healthy male albino rats of Wistar strain weighing between 150 and 200g were procured from the Animal House of the College of Veterinary Medicine, Federal University of Agriculture Abeokuta, Nigeria. These rats were treated in accordance with the internationally accepted principles for laboratory animal use and care (Guide for the Care and Use of Laboratory

Animals, 2006). They were housed in standard cages, under clean environmental conditions ( $23 \pm 1^\circ\text{C}$ , with  $55 \pm 5\%$  humidity and 12 h /12 h light/dark cycles), fed with rat chow and water *ad libitum* and allowed to acclimatize for seven days.

### Experimental Design and Animal Treatment

Animals were divided into five groups with six rats per group randomly. Group A was the control, fed with animal feed and water *ad libitum* only for fourteen days. Groups B, C, D and E were given graded levels of sub-lethal doses of paraquat (i.e 15, 25, 35 and 45 mg/Kg body weights respectively for fourteen days. The rats were sacrificed at the end of the 15<sup>th</sup> day after overnight fast under diethyl ether anesthesia. Blood samples were collected via cardiac puncture into clean EDTA bottles. These were centrifuged at 4000 rpm for 10minutes for plasma preparation for CRP, cholesterol and triglycerides assay. The animals were then dissected and livers and kidneys excised, mopped and preserved in Bouin fluid prior to histopathological examinations.

### Biochemical Assays

#### C-reactive protein (CRP) Determination

Plasma C-reactive protein concentration was determined using an immune-turbidimetric assay according to the method described by Hirshfield and Pepys (2003) using Cypress diagnostics reagent kits.

#### Cholesterol and Triglycerides Determination

Cholesterol and triglyceride concentrations were determined according to the methods of Jaffe (1984) and Allain *et al.* (1974) respectively using Fortress diagnostics kits.

#### Histopathological Studies

The livers and kidneys harvested from the sacrificed rats were fixed in Bouin fluid (5% picric acid + 10% formalin + 5% acetic acid) embedded in paraffin and then stained with hematoxylin and eosin (HE). Preparations were evaluated with a light field microscope and were photographed Olympus, Cs21 Camera.

#### Statistical Analysis

Values were expressed as Mean $\pm$ Standard Error. The level of homogeneity among the groups was tested using Analysis of Variance (ANOVA).

Where heterogeneity occurred, the groups were separated using Duncan Multiple Range Test (DMRT). All analysis was done using Statistical Package for Social Science (SPSS) version 16.0.

## RESULTS.

The results of the effects of paraquat on the plasma CRP, cholesterol and triglycerides levels in treated rats are presented in Table 1.

**Table 1:** Effects of Various Doses of Paraquat on Plasma Crp, Cholesterol and Triglycerides on Induced Albino Rats.

Group/parameter	CRP (mg/L)	Triglycerides (mg/L)	Cholesterol (mg/L)
Group A (Control)	12.38 ± 0.09 <sup>a</sup>	189.47 ± 2.59 <sup>a</sup>	8.61 ± 0.49 <sup>a</sup>
Group B (15 mg/Kg b.wt PQ)	12.91 ± 0.14 <sup>a,b</sup>	191.49 ± 1.49 <sup>a</sup>	12.61 ± 0.75 <sup>b</sup>
Group C (25 mg/Kg b.wt PQ)	14.81 ± 0.27 <sup>b</sup>	194.28 ± 1.03 <sup>b</sup>	13.45 ± 0.97 <sup>b</sup>
Group D (35 mg/Kg b.wt PQ)	14.32 ± 0.81 <sup>c</sup>	196.14 ± 2.05 <sup>b</sup>	15.43 ± 2.56 <sup>c</sup>
Group E (45 mg/Kg b.wt PQ)	18.82 ± 1.12 <sup>b</sup>	196.91 ± 1.69 <sup>b</sup>	19.35 ± 0.67 <sup>d</sup>

Values are expressed as mean ± SEM. Values along the same column with different superscripts (a,b, c) are significantly different at  $p < 0.05$ .

It was observed that in all the parameters determined, there was a difference between the control group (A) and other groups (B, C, D, E).

As the concentration of paraquat administered increased, the values of these parameters also increased. The higher the concentration of paraquat administered, the higher the increase in the level of the parameters observed. The control group (group A) showed a normal mean value of  $12.49 \pm 0.23$  mg/L for the plasma CRP, while the successive groups showed a significant increase in the levels of CRP with  $18.82 \pm 1.12$  mg/L showing the highest level of CRP of value.

Also, cholesterol and triglyceride concentrations in the treated groups when compared to the control showed significant ( $p < 0.05$ ) increases in their levels with the highest values of  $196.91 \pm 1.69$  mg/L and  $19.35 \pm 0.63$  mg/L for triglyceride and cholesterol respectively as observed in group administered highest concentration of PQ. Although, there was no significant difference in triglycerides levels between groups A and B and among groups C, D and E.

The liver and kidney sections of group A, B, C, D and E were presented in plates shown below.



1a

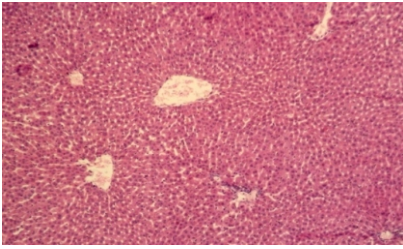


Plate 1a: Liver section of control group of rats showing no visible lesion

1c

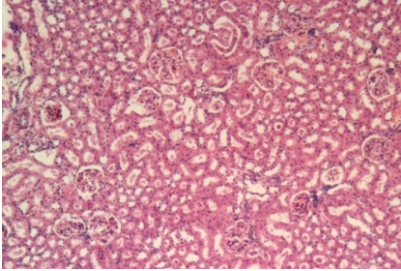


Plate 1c: Kidney section of rats administered sub-lethal dose (25mg/Kg) of PQ showing moderate diffuse vacuolar degeneration.

1e

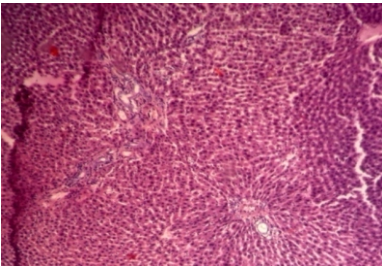


Plate 1e: Kidney section of rats administered below lethal dose (45mg/Kg) of PQ showing multiple foci necrosis with no evidence of regeneration and foci of duct proliferation.

2b

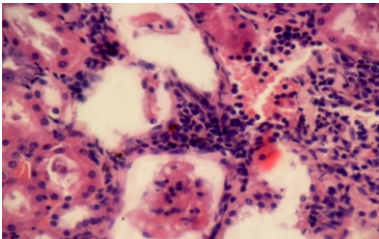


Plate 2b: Liver section of rats administered below sub-lethal dose (15mg/Kg) of PQ showing moderate diffuse hepatic vascular degradation and necrosis.

2d

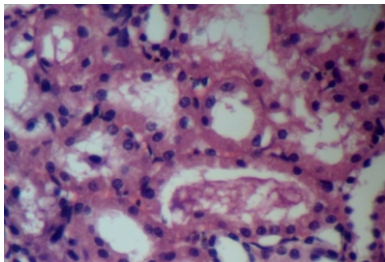


Plate 2d: Liver section of rats administered below sub-lethal dose (35mg/Kg) of PQ showing severe hepatic necrosis, tubular degeneration and odema.

1b

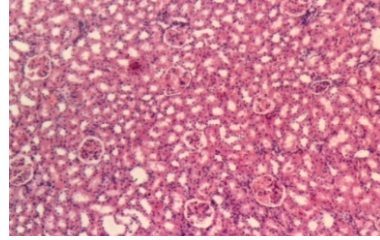


Plate 1b: Kidney section of rats administered below sub-lethal dose (15mg/Kg) of PQ showing moderate diffuse vacuolar degeneration.

1d

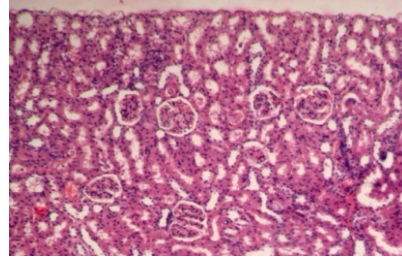


Plate 1d: Kidney section of rats administered below lethal dose (35mg/Kg) of PQ showing marked vacuolar degeneration and necrosis.

2a

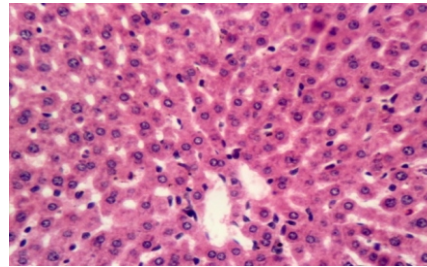


Plate 2a: Liver section of rats administered below sub-lethal dose (15mg/Kg) of PQ showing no visible degradation and necrosis with normal architecture.

2c

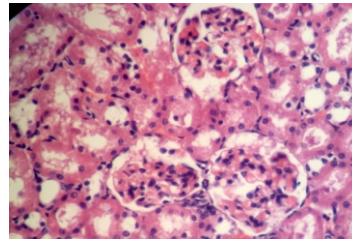


Plate 2c: Liver section of rats administered below sub-lethal dose (25mg/Kg) of PQ showing moderate diffuse protein cast in the hepatocytes

2e

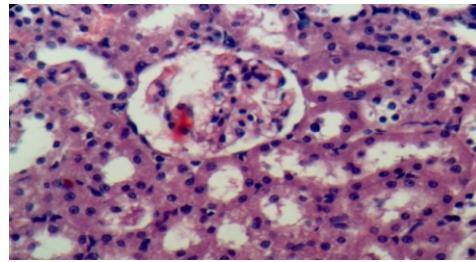


Plate 2e: Liver section of rats administered below sub-lethal dose (45mg/Kg) of PQ showing marked more severe vacuolar degeneration of the hepatocytes and foci duct proliferation.

## DISCUSSION

Paraquat (PQ) is highly toxic and enters the body mainly not only by swallowing or inhalation but also through damaged skin. The results from this study demonstrates that PQ treatment cause a significant increase in C-Reactive Protein (CRP), cholesterol and triglycerides levels as well as marked histological changes in liver and kidney as the dose of PQ increases down the group. This is similar to the report by Riahi *et al.* (2010) which revealed that high dose of paraquat could suppress both cellular and humoral activity of the immune system while low dose did not show any changes in organ weight, body weight and spleen cellularity. Also, toxicity of paraquat evaluated by dermal application of  $1/2 LD_{50}$  and  $1/10 LD_{50}$  for five days each week for four weeks was reported to induce swelling of pneumocytes, thickening of interalveolar septa and infiltration with lymphocytes and macrophages (Luty *et al.*, 1997).

The abnormal increase in the plasma CRP down the group with increased oral administration of PQ doses when compared to the control group is a sensitive indicator of hepatotoxicity or a diseased state. This may be due to degenerative changes and hypo-function of liver and kidneys as a result of consequent production of increased oxidative stress by PQ via generation of ROS. Paraquat induced toxicity is a manifestation of its ability to generate Reactive Oxygen Species (ROS). The generation of highly ROS results in toxicity in most organs (Rannels *et al.*, 1989). Pond (1990) revealed that PQ increase the production of certain oxygen derivatives that may harm cellular structure and that as a consequence of increased oxidative stress, PQ toxicity can cause increased level of CRP. This indicates an inflammation caused by PQ toxicity. Pepys *et al.*, (1983) have demonstrated that CRP is an acute-phase protein and is an exquisitely sensitive systemic marker of inflammation and tissue damage. CRP may have significant pro-inflammatory effects and bind to ligands exposed on cells as a result of infection, inflammation, ischemia and other pathologies and triggering complement activation. It may also exacerbate tissue damage, leading to more severe diseases (Pepys *et al.*, 1983). The increase in CRP level as found to be related to increase in triglycerides level can be related to a study that shows that CRP is associated with lipid responses

to low-fat and high-poly unsaturated fat diets (St-Onge *et al.*, 2009).

The study also revealed that increase in PQ concentration is closely followed by a concomitant increase in cholesterol and triglycerides. These biomarkers can be regarded as reliable indicators of the severity and prognosis of acute poisoning. A significant increase in cholesterol and triglycerides level observed indicated that PQ could predispose an animal to the risk of coronary heart disease. The high levels of triglycerides may be due to lack of production of Very Low Density Lipoproteins (VLDL). Rye *et al.* (1999) reported that when these lipoproteins are not produced, triglyceride is not transported and this results in accumulation of triglycerides in the tissues. The high cholesterol level observed may be attributed to high oxygen radicals generated and is also in agreement with the report of Adachi *et al.* (2000) that PQ administration in rats led to high level of cholesterol. Lee *et al.* (1991) and Kimura *et al.* (1999) also reported increased serum cholesterol in PQ-induced oxidative stress condition.

The liver and kidney are considered to be the principal target organs for PQ. In vertebrates, the liver is a highly metabolically active organ with a high activity of antioxidants and associated enzymes, so that it is the main organ responsible for detoxification of xenobiotics (Hargus *et al.*, 1994). The toxic effects of paraquat on liver histology showed centrolobular cholestasis, hepatocellular necrosis and macrophagic infiltration of portal areas, with the portal tracts increased in size due to abundance of collagen stroma, slight infiltration by lymphocytes and leukocytes (Bataller *et al.*, 2000). These results clearly showed that PQ has a harmful and stressful influence on the hepatic and renal tissue and is quite consistent with the report of Dragain *et al.*, (2006) in respect of paraquat liver toxicity.

Histological examination of the liver tissues in the control group (Group A) revealed a normal lobular structure with no visible lesion (Plate 1a). However, there was moderate diffuse vacuolar degeneration in the kidney sections of rats administered sub-lethal doses (15 mg/Kg and 25 mg/Kg) PQ (Plates 1b and 1c). More so, marked



vacuolar degeneration and necrosis with no evidence of regeneration were observed in the kidney section of group of rats administered below lethal doses (35 mg/Kg and 45 mg/Kg) PQ (Plates 1d and 1e). Although, the liver section of rats administered below sub-lethal dose (15 mg/Kg) of PQ showed no visible degeneration and necrosis (Plate 2a), those administered 25 mg/Kg PQ showed moderate diffuse protein cast in the hepatocytes (Plate 2c). Also, severe hepatic necrosis, vacuolar degeneration and foci duci proliferation were observed in the liver sections of groups of rats administered sub-lethal doses (35 mg/Kg and 45 mg/Kg) of PQ (Plates 2d and 2e). These observations were similar to the findings of Gokcimen *et al.* (2001) which suggest that a high dose of paraquat causes cell damage, fibrous tissue proliferation, acute hepatitis and irreversible cell death.

The present results showed that PQ induced many histological alterations in the kidney of rats. Examination of the kidney showed no visible lesion in the control group. The sub-lethal dose group showed a moderate tubular degeneration and cell death while the lethal dose group showed a severe glomerular disruption, tubular protein cast and kidney necrosis. This indicated that PQ caused damages to the kidney tissue but the severity increases as the concentration of PQ dose increases. Also, most of the renal blood vessels were more dilated, congested and engorged with blood with increasing PQ concentration establishing the dose-dependent toxicity. In the lethal dose group, most of the renal tubules were damaged and lost their characteristic appearance.

Their lining epithelial cells became undistinguished and their contents were intermixed with each other (Plate 1e). The walls of Bowman's capsule were eroded and the glomeruli were atrophied and in some sections, appeared as empty spaces containing amorphous cellular debris (Plate 1e). These results are similar to those previously reported by some researchers. For instance, Abdel-Mageid (1994) reported that kidney of paraquat-intoxicated rats revealed degeneration of renal tubules, shrunken glomeruli and congested dilated blood vessels. Also, Damin *et al.* (1992) emphasized that as a result of paraquat poisoning, renal damage occurs while Laurence

and Bennett (1992) reported that toxicity of paraquat caused renal tubular necrosis followed by kidney failure.

Inflammatory cells were observed in the interstitial tissue of kidney of paraquat-treated rats. Similar observation was described in human cases of intoxication with paraquat in the lung and considered as sign of toxicity and consequent activation of defensive mechanism (Borchard, 1974). More so, the observed toxic effects of paraquat on liver histology as revealed by centrolobular cholestasis, hepatocellular necrosis and macrophagic infiltration of portal areas could be attributed to the fact that portal tracts increased in size due to abundance of collagen stroma, slight infiltration by lymphocytes and leukocytes as reported by Bataller *et al.* (2000).

The results from this studies revealed that paraquat could elevate not only cholesterol and triglycerol but also C-reactive protein. This, confirms the fact that CRP levels increase during PQ-induced inflammatory conditions.

## REFERENCES

- Abdel-Mageid, S.A. 1994. Structural changes in the kidney of albino rat in response to the administration of paraquat herbicide. *J. Egypt. Germ. Soc. Zool.* 15: 153-175.
- Adachi, J., Tomita, M., Yamakawa, S., Asano, M., Narto, T. and Ueno, Y. 2000. 7dehydroperoxycholesterol as a marker of oxidative stress in rat induced by paraquat. *Free Radical Res.* 33: 321-327
- Allain, C.C., Poon, L.S., Clau, C.S.G., Richmond, W.Y. and Fu, P.D. 1974. Determination of total cholesterol. *Clin. Chem.* 20: 470.
- Ashton C, Leahy N. Paraquat [online]. Published 2000 [Cited 2005]. Available from: <http://www.inchem.org/documents/pims/chemical/pim399.htm#SectionTitle:7.2%20%20Toxicology>.
- Bataller, R., Bragulat, E., Nogue, S., Gorbis, M.N., Bruguera, M. and Rodes, J. 2000. Prolonged cholestasis after acute paraquat poisoning through skin absorption. *Am. J. Gastroenterol.* 95: 1340-1343.
- Borchard, F. 1974. Ultrastructural and microscopical findings in 3 cases of paraquat poisoning with prolonged lethal course. *Pneumologie* 150-185.

- Brooks, R. 1971. Ultrastructure of lung lesions produced by ingested chemicals. I. Effect of the herbicide paraquat on mouse lung. *Lab. Invest.* 25:535-545.
- Cameron 1987. Defective metabolism of hypertriglyceridemic low density lipoprotein in cultured human skin fibroblasts. *J. Clin. Invest.* 75: 1796-1803.
- Clark, D.G., T.F. Elligott and E. Weston-lhurst 1966. The toxicity of paraquat. *Br. J. Ind. Med.* 23: 126-132.
- Damain, F., B. Frank, H. Win fried, M. Hartmut and Laus, W. 1992. Failure of radiotherapy to resolve fatal lung damage due to paraquat poisoning. *Chest.* 100: 1146-1165.
- Dragin, N., Smani, M. and Dabernat, S.A. 2006. Acute oxidative stress is associated with cell proliferation in the mouse liver. *FEBS Lett.* 3845-3852.
- Fukushima, T., Tanaka, K., Lim, H. and Moriyama, M. 2002. Mechanism of cytotoxicity of paraquat. *Environ. Hlth. Preven. Med.* 7: 89-94.
- Guide for the Care and Use of Laboratory Animals*, 2006. The National Academic Press, Washington DC, 8<sup>th</sup> Edition, pp 41-103. www.nap.edu.
- Hirschfield, G.M. and Pepys M. B. 2003. C-reactive protein: a critical update centre for Amyloidosis and acute phase proteins. *J. Clin. Invest.* 111: 1805-1812.
- Jaffe, M. 1984. Uber den Wiederschog Welchen Pikrinsaure in normalem Ham erzeugt und uber eine neue Reaktion des kreatinins. *Physiol. Chem.* 10: 391-400.
- Kennelly P.J; Murray, Robert F.; Victor W. Rodwell; Kathleen M. Botham 2009. *Harper's Illustrated Biochemistry*. McGraw-Hill Medical. U.S.A.
- Kimura, Y., Araki, Y., Takenaka, A. and Igarashi, K. 1999. Protective effects of dietary Nasunin on paraquat-induced oxidative stress. *Biosci. Biotechnol. Biochem.* 63(5): 799 - 804.
- Laurence, D.R. and D.N. Bennett 1992. *Clinical Pharmacology*, 7th ed., Churchill Livingstone, Oxford univ. Press.
- Lee, W.T., Chei ,T.Y. and Kim, C.W. 1991. A study on the changes in rabbit's serum protein, lipids and its electrophoretic changes in acute praquat intoxication. *Hanyang Uidae Haksulchi. Hanyang Uidae Haksulch.* 11: 421-440.
- Lewis, C.P.L. and Nemery, B. 1995. Pathophysiology and biochemical mechanisms of the pulmonary toxicity of paraquat.: In Bismuth C, Hall A H (eds) *Paraquat Poisoning. Mechanism, Prevention and Treatment*. Dekker, M Inc. New York, pp.107-140.
- Luty S, Latuszynska J, Halliop J, Tochman A, Obuchowska D, Korczak B, Przylepa E, Bychawski E. 1997. Dermal toxicity of paraquat. *Ann Agric Environ Med.* 4: 217-27.
- Minakata K., O. Suzuki and F. Horio 2000. Saito Sandharada N. Increase in protection of ascorbate radical in tissues of rat treated with paraquat. *Free Radic Res.* 33: 179-185.
- Murray, R.E. and Gibson, J.E 1972. A comparative study of paraquat intoxication in rats, guinea pigs and monkeys. *Exp. Mol. Pathol.* 17: 317-325.
- Paraquat-Monograph (online). Published 2003 (Cited 2005). Available from: <http://www.panap.net/docs/monos/paraquatSep03.pdf>
- Paraquat-Monograph (online). Published 2006 (Cited 2006). Available from: <http://www.paraquat.com/>
- Pincus R. Matthew; McPherson, Richard A.; Henry, John Bernard 2007. *Henry's Clinical Diagnosis and Management by Laboratory Methods*. Saunders Elsevier.
- Riahi B, H Rafatpanah, M Mahmoudi, B Memar, A Brook, N Tabasi, et al. 2010. Immunotoxicity of paraquat after subacute exposure to mice. In *Food and Chemical Toxicology* 48 (6): 1627-1631.
- Robbe W.C., Meggs W.J. 2004. Insecticides, herbicides, rodenticides. In: Tintinalli J.E, Kelen G.D, Stapczynski J.S., Ma O.J., Cline D.M. (eds.) *Emergency Medicine: A Comprehensive Study Guide*. 6th ed. McGraw-Hill, New York.
- Roberts, T.R., Dyson, J.S. and Lane, M.C. 2002. Deactivation of the biological activity of paraquat in the soil environment: a review of long-term environmental fate. *J. Agric. Fd. Chem.* 50: 3623-3631.
- Thompson, D; Pepys, M.B and Wood S.P 1999. The physiological structure of human C-reactive Protein and its complex with phosphocholine. *Structure* 7(2):169-77.
- Sadava D, Hillis DM, Heller H.C., Berenbaum M.R. 2011. *Life: The Science of Biology 9th Edition*. Freeman, San Francisco pp. 105-114.